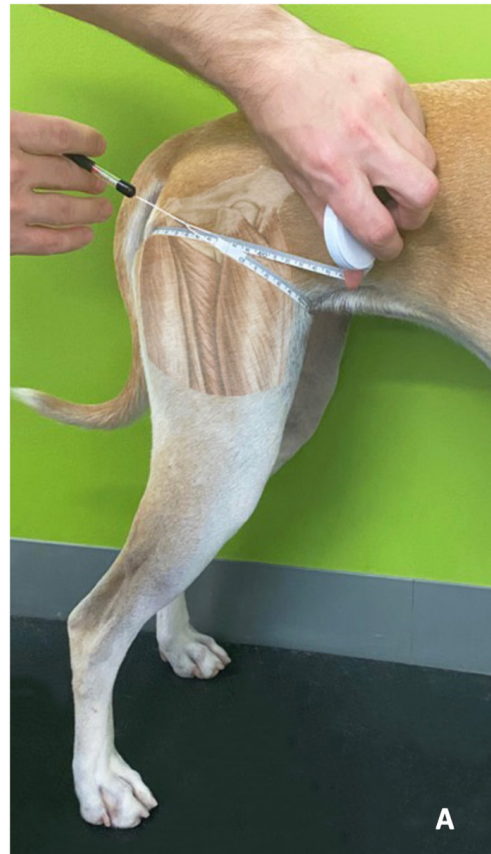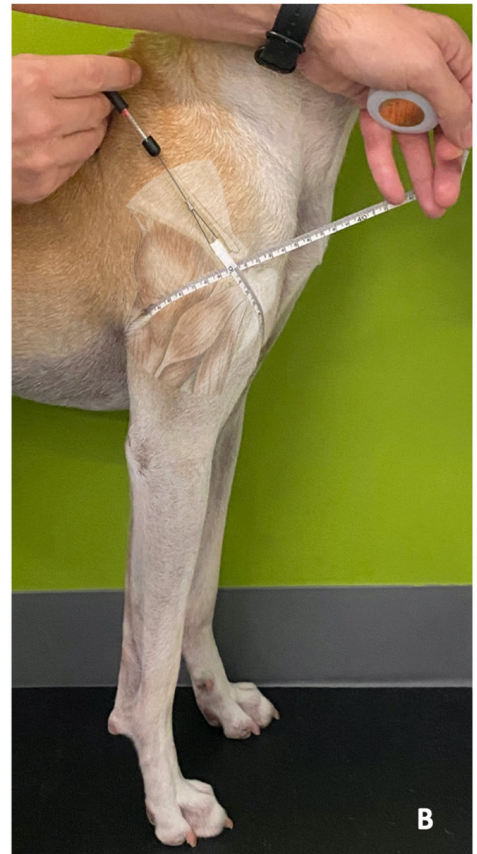


Supplementary material S1 – Figure S1: Illustrated example of a landmark-girth measurement technique for the canine pelvic limb (PL) (A) using the greater trochanter of the femur and for the canine thoracic limb (TL) using the acromion process of the scapula (B).



Anatomical image referenced from "Miller's Anatomy of the Dog", 4th Ed.



Anatomical image referenced from "Miller's Anatomy of the Dog", 4th Ed.